

# EUROPEAN JOURNAL OF CARDIO-THORACIC SURGERY

## **Modified maze procedure combined with mitral valve surgery via septal-superior approach**

Satoshi Kainuma, Takenori Yokota, Koichi Toda and Kazuhiro Taniguchi

*Eur J Cardiothorac Surg* 2009;36:198-199

DOI: 10.1016/j.ejcts.2009.03.047

**This information is current as of August 18, 2010**

The online version of this article, along with updated information and services, is located on the World Wide Web at:

<http://ejcts.ctsnetjournals.org/cgi/content/full/36/1/198>

The European Journal of Cardio-thoracic Surgery is the official Journal of the European Association for Cardio-thoracic Surgery and the European Society of Thoracic Surgeons. Copyright © 2009 by European Association for Cardio-Thoracic Surgery. Published by Elsevier. All rights reserved. Print ISSN: 1010-7940.

How-to-do-it

# Modified maze procedure combined with mitral valve surgery via septal-superior approach

Satoshi Kainuma, Takenori Yokota, Koichi Toda, Kazuhiro Taniguchi\*

Department of Cardiovascular Surgery, Japan Labor Health and Welfare Organization, Osaka Rosai Hospital,  
1179-3 Nagasone-cho, Kita-ku, Sakai, Osaka 591-8025, Japan

Received 26 January 2009; received in revised form 23 March 2009; accepted 25 March 2009; Available online 2 May 2009

## Abstract

Although a septal-superior approach provides excellent exposure of the mitral valve, it requires novel strategies for concomitant ablation in patients with atrial fibrillation. Utilizing a combination of bipolar radiofrequency and cryotherapy, we developed a novel technique for creating a biatrial lesion set via a septal-superior approach during mitral valve surgery. We treated 10 patients with functional mitral regurgitation and permanent atrial fibrillation with rhythm disturbance for a mean 87 months. A modified maze was successfully accomplished via a septal-superior approach in all. The mean follow-up period was 18 months, during which permanent pacemaker implantation was necessary for one due to sinus bradycardia. Sustained sinus rhythm, including atrial or atrial-based paced rhythm, was present in all immediately after surgery, in 70% at discharge, in 80% at 1 year after surgery, and in 90% at the latest follow-up examination. Our novel technique using a modified maze procedure in combination with mitral valve surgery via a septal-superior approach was safe and useful for eliminating atrial fibrillation, with a relatively low frequency of sinus node dysfunction.

© 2009 European Association for Cardio-Thoracic Surgery. Published by Elsevier B.V. All rights reserved.

**Keywords:** Arrhythmia surgery (including maze); Atrial fibrillation; Cardiomyopathy; Mitral regurgitation; Ischemic; Pacemaker

## 1. Introduction

The Maze III procedure is an established and effective surgical method to eliminate atrial fibrillation [1], which is frequently encountered in patients with mitral valve disease [2]. Recently, use of new devices such as radiofrequency ablation catheters for less invasive surgical treatment has become widespread, though we have used a septal-superior approach, which provides a large operative field in nearly all anatomic conditions [3] as a first choice since 2005. We have also performed concomitant surgical ablation in patients with atrial fibrillation utilizing a combination of bipolar radiofrequency and cryotherapy. Herein, we present our novel technique for biatrial lesion set creation via a septal-superior approach during mitral valve surgery.

## 2. Technique

For biatrial lesion set creation, we first electrically isolate the right and left pulmonary veins (Fig. 1a,b) using bipolar radiofrequency (Atricure<sup>®</sup>, Century Medical Inc., Tokyo, Japan)

under a standard cardiopulmonary bypass. Snares previously placed around the inferior and superior vena cavae are tightened, and a right atrial incision is started at the right atrial appendage, then extended cephalad toward the left atrial dome and caudad toward the inferior vena cava. Bipolar radiofrequency is used to connect the lesion toward the tricuspid annulus from the right atrial incision (Fig. 1c), with a cryo-lesion applied at the tricuspid annulus anterior portion using a reusable cryoprobe (Frigitronics Cardiac Cryosurgical System; Tonokura Ika Co., Ltd., Tokyo, Japan) at  $-60^{\circ}\text{C}$  for 2 min. A vertical right atriotomy is extended down inferiorly toward the intra-atrial septum from the first atrial incision. Then, from the inferior aspect of the vertical right atriotomy, a bipolar clamp is placed to the superior vena cava (Fig. 1d), while avoiding sinus node damage. The clamp is rotated and extended in a similar fashion onto the inferior vena cava (Fig. 1e).

Under heart arrest, a left atrial appendage is safely amputated from outside the heart. The bipolar radiofrequency device is introduced into the left superior pulmonary vein through the amputated orifice, with one jaw inside and one outside the atrium (Fig. 1f). This ablation should overlap the previously performed encircling ablation of the left pulmonary veins. The left atrial appendage is oversewn using a running monofilament suture. The atrial septum is incised vertically through the fossa ovalis, and two joint incisions are extended

\* Corresponding author. Tel.: +81 72 252 3561; fax: +81 72 255 3349.  
E-mail address: s.kainuma@hotmail.co.jp (S. Kainuma).

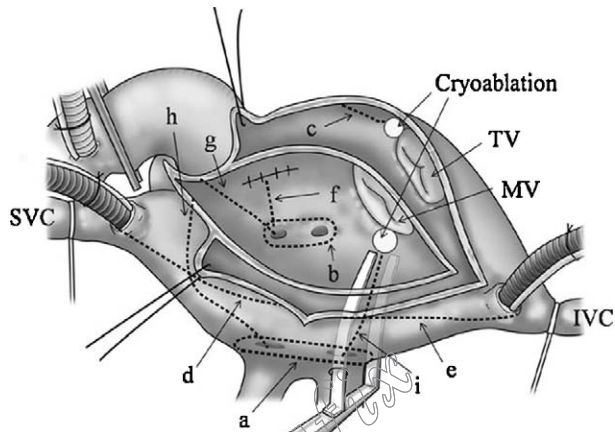


Fig. 1. Right and left atrium under septal-superior approach. Dotted lines indicate connecting lesions made with bipolar radiofrequency, while ovals indicate cryolesions created on left and right atrial isthmuses. (IVC = inferior vena cava; SVC = superior vena cava; MV = mitral valve; TV = tricuspid valve.)

Table 1  
Patient characteristics and operative results.

Patients (n)	10
Male (%)	8 (80%)
Age (years)	62 ± 8
Rhythm characteristics	
Duration of atrial fibrillation (months)	87 ± 52
Permanent atrial fibrillation (%)	10 (100%)
Echocardiographic findings	
Left atrial diameter (mm)	53 ± 3
Right atrial diameter (mm)	49 ± 4
Left ventricular end diastolic diameter (mm)	64 ± 5
Left ventricular end systolic diameter (mm)	49 ± 6
Left ventricular ejection fraction (%)	34 ± 4
Degree of mitral regurgitation	3.8 ± 0.5
Degree of tricuspid regurgitation	2.9 ± 0.6
Concomitant surgery	
Tricuspid annuloplasty (%)	10 (100%)
Aortic valve replacement (%)	1 (10%)
Coronary artery bypass grafting (%)	1 (10%)
Operative results	
Operative mortality	0 (0%)
Hospital mortality	0 (0%)
Late mortality	0 (0%)
Freedom from atrial fibrillation	
Immediately after surgery (%)	100%
At discharge (%)	70%
At 1 year after surgery (%)	80%
At the latest follow-up (%)	90%
Cardiac rhythm at the latest follow-up	
Sinus/atrial rhythm (%)	8 (80%)
Atrio-ventricular sequential pacemaker (%)	1 (10%)
Atrial fibrillation (%)	1 (10%)

onto the dome of the left atrium. The orifice of the left atrial appendage is then oversewn using a purse string suture from inside the left atrium. Two connecting lesions are created from the left atrial roof into the right and left superior pulmonary veins (Fig. 1g,h). Next, a 1 cm incision is made distally in the right inferior pulmonary vein and a bipolar device applied to create a connecting lesion from the incision toward the mitral annulus posterior portion (Fig. 1i). Finally, a cryolesion is added in the mitral annulus posterior portion, as described above. Subsequently, mitral valve surgery combined with another procedure is performed.

### 3. Comment

We applied our technique in 10 consecutive patients with functional mitral regurgitation associated with dilated cardiomyopathy between March 2005 and June 2008, after receiving informed consent. Postoperatively, an electrocardiogram examination was conducted every 6 months, with a Holter electrocardiogram used for patients with symptomatic or unknown arrhythmia.

Data for preoperative characteristics and postoperative cardiac rhythm are summarized in Table 1. There was no hospital mortality, while permanent pacemaker implantation was necessary for one patient due to sinus bradycardia. There were no thromboembolic complications during the mean follow-up period of 18 months. Oral anticoagulation therapy was given for 6 months after surgery in all cases.

The present study has some limitations, as the small number investigated does not allow for definite conclusions regarding the effects of our technique, and continued follow-up findings are required to confirm the results. Also, we did not include a control group to validate the benefits of a total and complete approach involving both atria. However, a biatrial lesion set was required in all patients, because of both the long history of atrial fibrillation and a dilated right atrium. Finally, our technique requires radiofrequency bipolar and cryo devices, which may increase the cost.

In conclusion, our novel technique is considered to be safe, effective, and useful in eliminating atrial fibrillation with a relatively low frequency of sinus node dysfunction.

### References

- [1] Cox JL, Schuessler RB, D'Agostino Jr HJ, Stone CM, Chang BC, Cain ME, Corr PB, Boineau JP. The surgical treatment of atrial fibrillation. III. Development of a definitive surgical procedure. *J Thorac Cardiovasc Surg* 1991;101:569–83.
- [2] Brodell GK, Cosgrove D, Schiavone W, Underwood DA, Loop FD. Cardiac rhythm and conduction disturbances in patients undergoing mitral valve surgery. *Cleve Clin J Med* 1991;58:397–9.
- [3] Guiraudon GM, Ofiesh JG, Kaushik R. Extended vertical transatrial septal approach to the mitral valve. *Ann Thorac Surg* 1991;52:1058–60.

**Modified maze procedure combined with mitral valve surgery via septal-superior approach**

Satoshi Kainuma, Takenori Yokota, Koichi Toda and Kazuhiro Taniguchi

*Eur J Cardiothorac Surg* 2009;36:198-199

DOI: 10.1016/j.ejcts.2009.03.047

**This information is current as of August 18, 2010**

<b>Updated Information &amp; Services</b>	including high-resolution figures, can be found at: <a href="http://ejcts.ctsnetjournals.org/cgi/content/full/36/1/198">http://ejcts.ctsnetjournals.org/cgi/content/full/36/1/198</a>
<b>References</b>	This article cites 3 articles, 2 of which you can access for free at: <a href="http://ejcts.ctsnetjournals.org/cgi/content/full/36/1/198#BIBL">http://ejcts.ctsnetjournals.org/cgi/content/full/36/1/198#BIBL</a>
<b>Subspecialty Collections</b>	This article, along with others on similar topics, appears in the following collection(s): <b>Cardiac - other</b> <a href="http://ejcts.ctsnetjournals.org/cgi/collection/cardiac_other">http://ejcts.ctsnetjournals.org/cgi/collection/cardiac_other</a> <b>Electrophysiology - arrhythmias</b> <a href="http://ejcts.ctsnetjournals.org/cgi/collection/electrophysiology_arrhythmias">http://ejcts.ctsnetjournals.org/cgi/collection/electrophysiology_arrhythmias</a> <b>Valve disease</b> <a href="http://ejcts.ctsnetjournals.org/cgi/collection/valve_disease">http://ejcts.ctsnetjournals.org/cgi/collection/valve_disease</a>
<b>Permissions &amp; Licensing</b>	Information about reproducing this article in parts (figures, tables) or in its entirety can be found online at: <a href="http://ejcts.ctsnetjournals.org/misc/Permissions.shtml">http://ejcts.ctsnetjournals.org/misc/Permissions.shtml</a>
<b>Reprints</b>	Information about ordering reprints can be found online: <a href="http://ejcts.ctsnetjournals.org/misc/reprints.shtml">http://ejcts.ctsnetjournals.org/misc/reprints.shtml</a>

EUROPEAN JOURNAL OF  
CARDIO-THORACIC  
SURGERY